



International Journal of Medical and All Body Health Research

Orthodontic Management of Class I malocclusion with crowding and Unesthetic smile: A case report

Nabin Kumar Chaudhary

Department of Dental, Hetauda Hospital, Hetauda, Nepal

* Corresponding Author: **Nabin Kumar Chaudhary**

Article Info

ISSN (online): 2582-8940

Volume: 04

Issue: 04

November-December 2023

Received: 03-11-2023;

Accepted: 04-12-2023

Page No: 45-49

Abstract

Crowding occurs when the teeth and arches are not matched in size. A class I malocclusion with crowding is treated by comprehensive orthodontics using either extractions or non-extractions as the primary therapy strategies. This is an instance of skeletal and dental class I malocclusion with crowding, protrusive lips, decreased nasolabial angle, and an unsightly smile that was treated with first premolars extraction and fixed orthodontic appliance. First premolar extraction and one-stage retraction were successful in treating the class I malocclusion with crowding and an unkempt smile. Transpalatal arch in maxilla, lingual holding arch in mandible along with second molar bonding provided maximum anchorage for en-mass retraction in this case.

Keywords: Crowding; En-mass retraction; Maximum anchorage; Unesthetic smile

Introduction

When there is mismatch between the size of the teeth and arches, crowding results ^[1]. Since facial esthetics is seen as a determining factor in both society's impression of a pleasing visage and a person's opinion, might affect a person's ability to form and maintain social interactions ^[2]. Crowding is the most common kind of malocclusion ^[3]. The multifactorial etiology involves shorter arches, maturing occlusions, mesial force vectors, muscle balance, morphology, tooth loss, and retention ^[4]. A class I malocclusion with crowding is treated by comprehensive orthodontics using either extractions or non-extractions as the primary therapy strategies ^[2]. Also, the best course of treatment for dental crowding depends on the severity of the issue, the patient's age, profile, and face esthetics ^[2]. This is an instance of skeletal and dental class I malocclusion with crowding and an unsightly smile that was treated with first premolars extraction and a fixed orthodontic appliance.

Case Report

A 23-year-old female patient's main concern was that her upper and lower front teeth were crooked. Patient's profile was convex, acute nasolabial angle, and competent lips. Tooth 18 and 28 were unerupted. 46 was endodontically treated with crown. The crowding was present in both arches. Molar relation was class I, canine class II bilaterally and incisor class me with overjet 2.5 mm and overbite 2 mm /25%. Upper dental midline and face midline were in line, with the lower dental midline shifted to right by 2mm. Lip line was average, and non-consonant smile arc on smiling. All teeth aside third molars were in Demirjian stage H in orthopantomogram (OPG). Lateral Cephalogram detected CVM CS stage 6 (Figure 1).

The diagnosis was skeletal class I (ANB= 3°) with vertical growth pattern (FMA= 30°) (Table 1); Angle's class I malocclusion with proclined and forwardly placed upper and lower incisors; protrusive upper and lower lips and decreased nasolabial angle. Treatment objectives included correction of crowding, position of incisors, and lips, and reduction of nasolabial angle. Corrective orthodontics intended to involve the extraction of first premolars. Maximum anchorage was intended by placing the transpalatal arch (TPA), the lingual holding arch (LHA), and banding the second molars. Bonding was done with MBT 0.022" slot bracket.

To level and align both arches, 0.014" Nickel Titanium (NiTi), 0.016" NiTi, and lastly 0.017"x0.025" NiTi were employed. 22 and 42 were not engaged in the archwire initially. 22 and 42 were engaged with the archwire after partial retraction of 23 and 43 in 0.018" Stainless Steel (SS) archwire. En-mass retraction was accomplished using 0.019"x0.025" SS archwire (Figure 2). The appliance was activated in one month. Before the appliance was debonded,

OPG indicated the roots were parallel to one another. In the end, posterior teeth were settled using 3/16" diameter and 4.5 oz force elastics. Both the upper arch and lower arch were retained using lingual bonded retainers. In the end, both sides had class I canine and molar relationships. The course of treatment lasted for 25 months. The only unanticipated event of the case was root resorption wrt 15 (Figure 3).

Table 1: Comparison of pre and post treatment cephalometric values

Parameters	Normal value	Initial value	Post value	Difference
Sella Nasion Point A angle (SNA)	82°±2°	81°	81°	0°
Sella Nasion Point B angle (SNB)	80°±2°	78°	78°	0°
Point A Nasion Point B angle (ANB)	2°±2°	3°	3°	0°
Frankfort Mandibular Plane angle (FMA)	25°	30°	31°	+1°
Upper incisor to Nasion Point A (NA)	22°/4mm	32°/10mm	22°/8mm	-10°/-2mm
Lower incisor to Nasion Point B (NB)	25°/4mm	36°/10mm	28°/6mm	-8°/-4mm
Lower incisor to point A-pogonion (A-Pog)	0.4±1.8mm	7mm	3.5mm	-3.5mm
Nasolabial angle	102°±8°	84°	95°	+11°
Steiner's S line to				
Upper lip	0mm	3mm	2mm	-1mm
Lower lip	0mm	2mm	0mm	-2mm

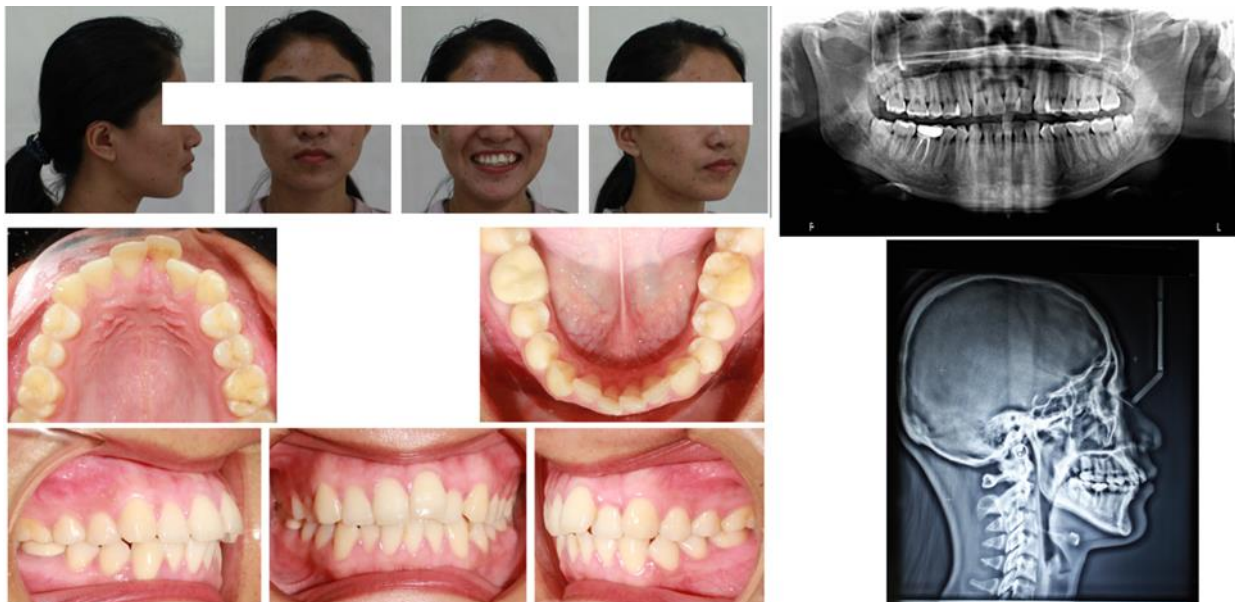


Fig 1: Pre-treatment records

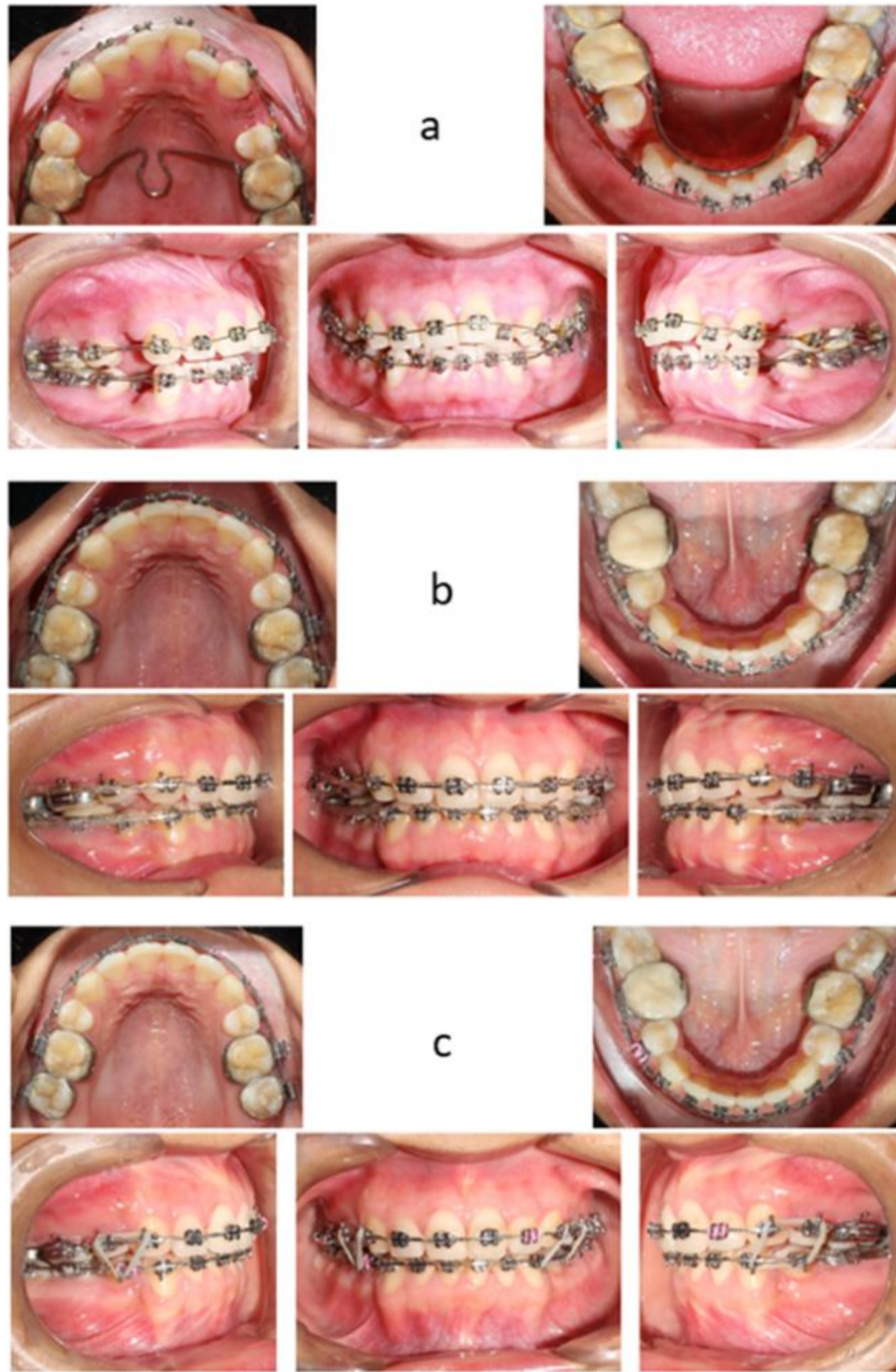


Fig 2: Mid-treatment records

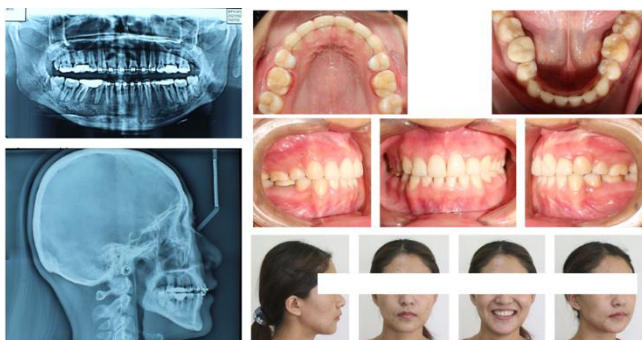


Fig 3: Post treatment records

Discussion

Narmada *et al* addressed crowding in class I malocclusion with two upper and one lower premolar extraction, whereas

our case was treated with four premolar extraction [1]. This was because their instance previously had a missing lower left first molar [1]. Pramustika and Widayati extracted upper second premolars and lower first premolars to alleviate severe crowding in the maxillary and mandibular arches [2]. In our case, first premolars were removed so that the space could be used to treat crowding and to prepare for anchorage. Bittencourt *et al.* treated a class I malocclusion with increased overjet, overbite, and severe mandibular crowding using non-extraction mode of treatment with slight retraction of upper incisors and intrusion and protrusion of the lower incisors until all crowding was eliminated [4]. But in their instance, the profile's convexity increased, contrary to what we wanted in our situation [4]. AOUAME *et al.* used a non-extraction method of therapy to correct a class I malocclusion with retained deciduous teeth [3]. However, in contrast to our

situation, their case's goal was to preserve the patient's profile [3]. To rectify bimaxillary protrusion with potentially incompetent lips and elevated lip strain, Jawale *et al* treated class I malocclusion with first premolars extraction [5]. However, our goal was to improve the patient's crowding and profile, as opposed to their situation, where the goal was to enhance the competency of the lips [5]. First premolar extraction was used by Huang *et al* to address a class I malocclusion with crowded and protruding upper and lower incisors. [6] The only distinction was that while we retracted the anterior teeth in one stage, they did so in two stages [6]. With the extraction of compromised teeth and a rapid maxillary expansion appliance, Shah *et al* were able to cure class I malocclusions with crowding and bilateral posterior crossbites [7]. This was distinct from our instance because there were no crossbites or compromised teeth [7]. Alam *et al.* managed crowding and class I malocclusion by extracting

four premolars [8]. The only change was that we used E-chain in our case instead of their NiTi coil springs for retraction. [8] Triwidiyanto and Narmada used the non-extraction technique of treatment to address class I malocclusion with crowding. [9] This technique of therapy was explored because there was only mild crowding and the goal of the treatment was to maintain the profile, which was not the situation in our case [9]. Four premolars were removed by Sitasari and Narmada to address a class I malocclusion with significant crowding and bimaxillary protrusion [10]. The only difference was that we retracted the anterior teeth in one stage while they employed two-stage retraction [10].

Crowding in the arches was eased with normal incisor position, the patient's grin improved to consonant, and nasolabial angle improved following treatment. The patient was content because her smile esthetics improved (Figure 4 and 5).

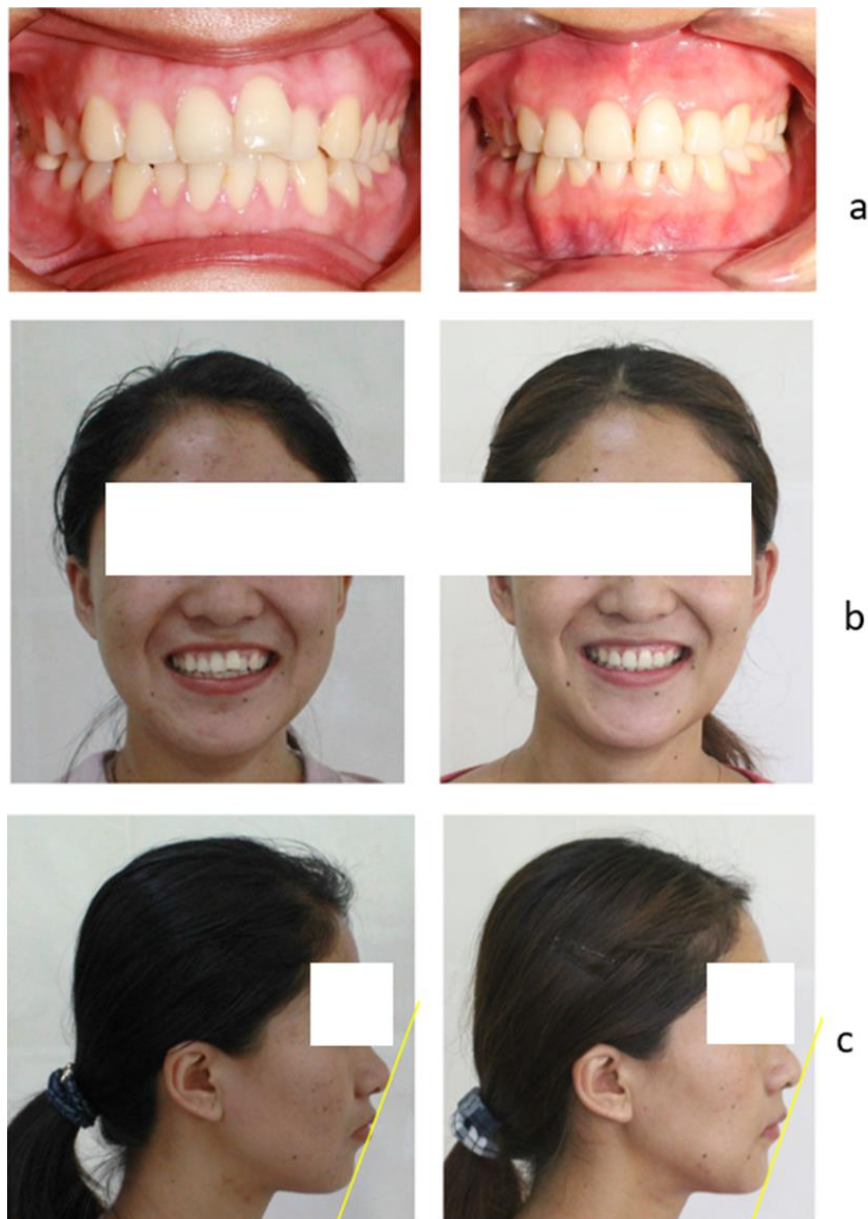

Fig 4: Comparison between pre and post treatment records

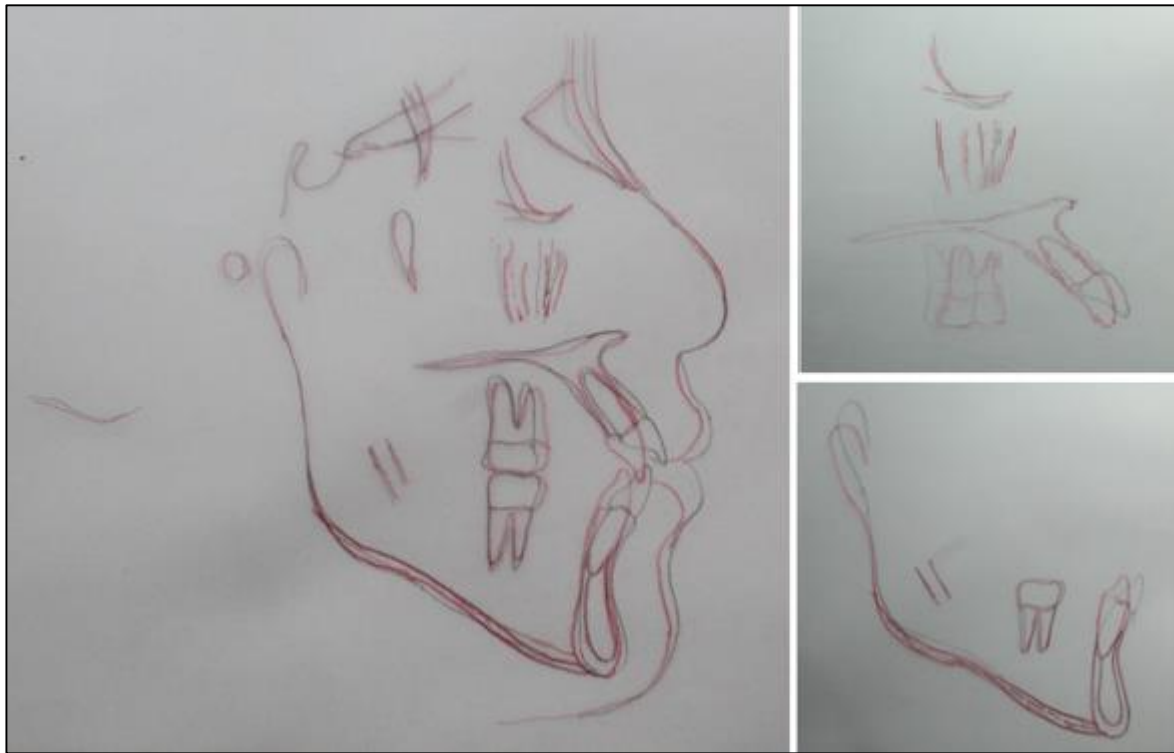


Fig 5: Superimposition (Black: before treatment; Red: After treatment)

Acknowledgements

The patient's cooperation during treatment deserves praise, and I thank her for it.

Conflict of interest: None

Consent: For the images and the case report's publishing, informed consent has been obtained.

References

1. Narmada IB, Ramadhani V, Pratiknjo IS, Prastiwi W. Treatment of a Patient with Class I Malocclusion with Moderate Crowding and Missing First Molar: A Case Report. *Acta Med Philipp.* 2023; 57(1):74-9.
2. Pramustika A, Widayati R. Treatment of a Class I Malocclusion with Severe Crowding using Passive Self-Ligating Brackets. *J Dent Indones.* 2020; 27(2):109-13.
3. AOUAME AE, Bouchghel L, ALAMI S, QUARS FE. Management of Dento-Maxillary Disharmony in Angle Class I malocclusion with Normobite: A Case Report. *American Journal of Educational Research.* 2021; 9(12):725-9.
4. Bittencourt MAV, Farias ACR, Castellucci BM. Conservative treatment of a Class I malocclusion with 12 mm overjet, overbite and severe mandibular crowding. *Dental Press J Orthod.* 2012; 17(5):43-52.
5. Jawale B, Rodrigues L, Belludi A, Ashtekar S, Patil A, Suryawanshi RK. "Treatment of Severe Crowding and Bimaxillary Dental Protrusion in a Patient with Angle's Class I Malocclusion and a Vertical Growth Pattern" – A Case Report on Orthodontic Camouflage. *Saudi J Oral Dent Res.* 2021; 6(5):203-10.
6. Huang YW, Kuo CL, Liu IH, Tsai YL, Wang CL, Yang CH. Orthodontic Treatment of Severe Bimaxillary Dentoalveolar Protrusion with Skeletal Class II Malocclusion. *Taiwanese Journal of Orthodontics.* 2022; 34(1):60-8.
7. Shah N, Ong DV, Freer E. Interdisciplinary management of an adult patient with significant restorative treatment needs and a complex malocclusion. *Aust Dent J.* 2017; 62(2):233-40.
8. Alam MK, Nowrin SA, Shahid F, *et al.* Case report Treatment of Angle class I malocclusion with severe crowding by extraction of four premolars: A case report. *Bangladesh Journal of Medical Science.* 2018; 17(4):683-7.
9. Triwidiyanto E, Narmada IB. Treatment of class I malocclusion with mild crowding and midline shift. *Dentino (Jur. Ked. Gigi).* 2020; 5(2):145-52.
10. Sitasari PI, Narmada IB. Management of Angle Class I Malocclusion with Severe Crowding and Bimaxillary Protrusion by Extraction of Four Premolars: A Case Report. *Acta Medica Philippina.* 2019; 53(5):444-9.