

Assessment of Ultrasound-Guided Thoracic Paravertebral Block as a Pain Management Strategy in Tracheo-Esophageal Fistula Repair

Dr. Abhitasha V. Gopal [1*], Dr. Shailja Sharma [2], Dr. Vivek Loomba [3], Dr. Vibhav Gupta [4], Dr. Patel Akashkumar Mukeshbhai [5], Dr. Shubham Nagpal [6]

[1] Postgraduate Resident (Anaesthesiology), Saraswathi Institute of Medical Sciences, Hapur, Uttar Pradesh, India
[2] Professor and HOD (Anaesthesiology), Saraswathi Institute of Medical Sciences, Hapur, Uttar Pradesh, India
[3] Senior Resident (General Surgery), Saraswathi Institute of Medical Sciences, Hapur, Uttar Pradesh, India
[4-6] Postgraduate Resident (Anaesthesiology), Saraswathi Institute of Medical Sciences, Hapur, Uttar Pradesh, India

* Corresponding Author: **Dr. Abhitasha V. Gopal**

Article Info

ISSN (online): 2582-8940
Volume: 06
Issue: 03
July - September 2025
Received: 11-05-2025
Accepted: 12-06-2025
Published: 05-07-2025
Page No: 17-20

Abstract

Ultrasound has become an indispensable tool in modern anaesthetic practice, significantly enhancing the safety and precision of various regional anaesthesia techniques. Its widespread adoption in the perioperative setting has minimized procedural complications associated with traditional blind approaches. Among these techniques, the ultrasound-guided thoracic paravertebral block (TPVB) has demonstrated excellent efficacy in providing perioperative analgesia, particularly following thoracic procedures. TPVB can be delivered as a single-dose injection or through continuous infusion using a catheter-based technique. The block involves the deposition of local anaesthetic into the paravertebral space, adjacent to the spinal nerve roots, which lack protective sheaths and are highly responsive to local anaesthetics. A single-shot TPVB can typically cover 4 to 6 dermatomes, offering substantial analgesic benefit. This case series presents the use of single-shot ultrasound-guided unilateral thoracic paravertebral blocks as an effective analgesic strategy in neonates undergoing tracheoesophageal fistula (TEF) repair. The implementation of ultrasound-guided regional anaesthesia techniques such as TPVB has significantly enhanced postoperative outcomes by ensuring effective perioperative pain control and reducing opioid exposure in vulnerable paediatric populations.

DOI: https://doi.org/10.54660/IJMBHR.2025.6.3.17-20

Keywords: Paravertebral Block, Paediatrics, Perioperative Pain Control, Tracheo-Esophageal Fistula, Ultrasound

Introduction

The integration of ultrasound technology into anaesthetic practice has significantly transformed perioperative care. Anaesthesiologists now routinely employ ultrasound not only as a diagnostic modality to facilitate early detection of complications and enhance patient safety but also as a crucial tool in regional anaesthesia and pain management. Ultrasound-guided regional anaesthesia techniques are increasingly favored over traditional blind techniques due to improved precision and safety.

The real-time visualization of neural structures, along with the accurate deposition and spread of local anaesthetic agents, has greatly improved the efficacy of nerve blocks. Peripheral nerve stimulators may further aid in the identification and confirmation of target nerves. For fascial plane blocks, ultrasound enables clear visualization of drug dispersion within the interfascial planes. When continuous analgesia is required, the placement and monitoring of ultrasound-compatible catheters are readily achievable under direct imaging guidance.

Among these techniques, ultrasound-guided thoracic paravertebral blocks (TPVB) have gained prominence, particularly in

thoracic and upper abdominal surgeries. TPVBs offer effective perioperative analgesia, whether administered as a single-shot injection or via a continuous catheter. Real-time imaging of the paravertebral space and observation of local anaesthetic distribution help anticipate the effectiveness of the block.

The extensive use of opioids in thoracic surgery often leads to delayed extubation and increases the risk of postoperative pulmonary complications, posing a significant challenge in pain management. In this context, regional techniques such as TPVB offer a promising alternative by minimizing opioid requirements and improving postoperative outcomes.

We present a series of two cases involving right thoracotomy performed for tracheoesophageal fistula repair, where postoperative pain was effectively managed using a single-shot, ultrasound-guided, right-sided thoracic paravertebral block.

CASE REPORT

Case 1

A 4-day-old neonate, weighing 3.5 kg, referred for surgical management of a tracheoesophageal fistula (TEF), was scheduled for right thoracotomy and fistula repair. Preoperative evaluation revealed normal age-appropriate hematological parameters. Chest radiograph demonstrated an opacity in the right upper apical zone with coiling of the orogastric tube in the upper esophageal pouch. Auscultation revealed fine crepitations bilaterally. Room air oxygen saturation was 88%, which improved to 92% with oxygen supplementation via a head box at 10 L/min.

Preoperative echocardiography identified a small secundum atrial septal defect (2.2 mm) with a left-to-right shunt and normal pulmonary artery pressure. The parents were appropriately counseled regarding the anaesthetic plan, and informed written consent was obtained. Cross-matched blood products were arranged in anticipation of potential transfusion. As the neonate was kept nil per oral (NPO), maintenance fluids and caloric requirements were managed intravenously.

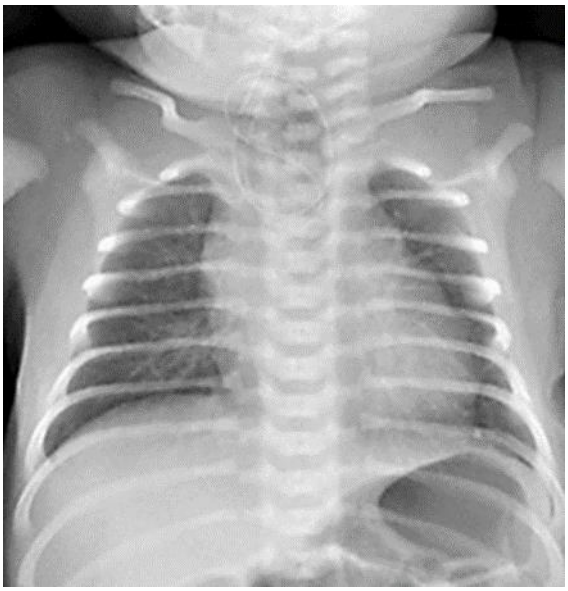

Fig 1: Chest radiograph showing opacity in the right upper zone and coiling of the orogastric tube

Upon arrival in the operating theater, standard ASA monitoring was established. Intravenous access was started and anaesthesia induction was achieved with Propofol 10 mg, Fentanyl 4 mcg, and Succinylcholine mg, followed by endotracheal intubation using an uncuffed 3.5 mm internal diameter tube, secured after bilateral chest auscultation confirmed correct placement.

The neonate was positioned in the left lateral decubitus position for ultrasound-guided thoracic paravertebral block (TPVB). Using a high-frequency linear ultrasound probe, scanning was performed at the T4 level. After identifying the spinous process, the probe was tilted obliquely to visualize the transverse process and pleura. Under in-plane guidance, a 26G Quincke spinal needle was introduced obliquely into the paravertebral space, and 2.0 ml of a local anaesthetic mixture (0.25% Bupivacaine and 1% Lignocaine with adrenaline) was administered after confirming drug spread and tenting of pleura.

The neonate remained in the same lateral position for the surgical procedure. Anaesthesia maintenance was achieved using oxygen, isoflurane, and vecuronium with assist-controlled ventilation. Two episodes of intraoperative desaturation (up to 80%) occurred and were managed with bag-mask ventilation and release of surgical traction on the right lung. Hemodynamic stability was maintained throughout the 90-minute procedure.

Postoperatively, the infant was transferred to the surgical intensive care unit (SICU) with the endotracheal tube in situ. Extubation was successfully performed later that day after the return of airway reflexes. Analgesia was required only once in the first 24 hours—a single intravenous dose of Fentanyl (5 mcg)—along with scheduled Paracetamol (20 mg/kg).

On postoperative day 5, oral methylene blue (0.5 ml) was administered to assess anastomotic integrity. Oral feeding was started after confirmation of no leakage. The chest drain was removed on the same day. The neonate was shifted to the ward on postoperative day 8 and discharged home later.

Case 2

A 7-day-old neonate weighing 3.0 kg, referred with a diagnosis of tracheoesophageal fistula (TEF), was scheduled for right thoracotomy and surgical repair. Pre-anaesthetic evaluation included a chest radiograph, which showed bilateral upper zone opacities along with coiling of the orogastric tube in the upper esophageal pouch, suggestive of esophageal discontinuity. Auscultation revealed fine bilateral crepitations. Peripheral oxygen saturation on room air was 84%, improving to 92% with supplemental oxygen delivered via a head box.

Echocardiographic examination identified multiple congenital cardiac anomalies, including an atrial septal defect (ASD), ventricular septal defect (VSD), and a patent ductus arteriosus (PDA), all with a left-to-right shunt and normal pulmonary artery pressure.

Anaesthesia was induced intravenously, and the airway was secured with endotracheal intubation. For intraoperative analgesia, a right-sided ultrasound-guided thoracic paravertebral block (TPVB) was performed at the T4 level. Using an in-plane technique, 1.3 ml of a local anaesthetic mixture comprising 0.25% Bupivacaine and 1% Lignocaine with Adrenaline was administered into the paravertebral space.

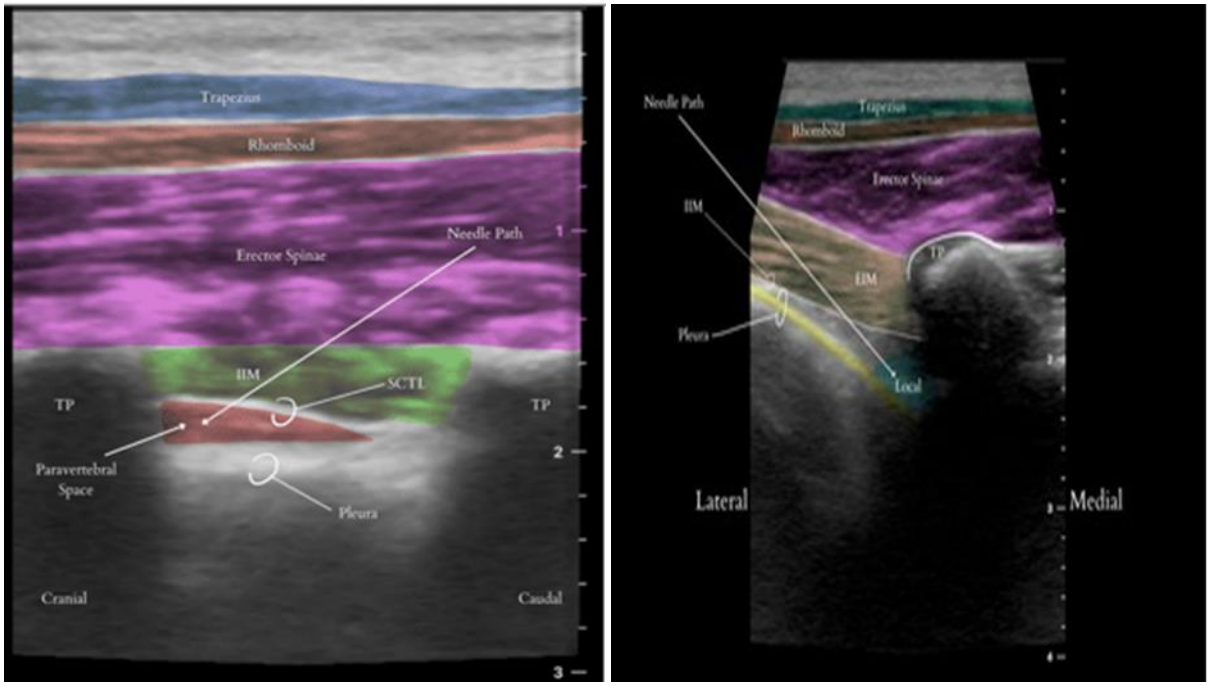

Fig 2 &3: Ultrasound images showing Paravertebral space in sagittal and transverse view and the needle path. SCTL- Costotransverse ligament, IICM- Intercostal muscle, TP-Transverse process

Intraoperatively, the patient experienced multiple episodes of desaturation, which were managed with intermittent bag-mask ventilation and release of surgical traction. Two episodes of bradycardia were observed and promptly treated with intravenous Atropine. The surgical procedure lasted approximately 110 minutes.

Postoperatively, the neonate was transferred to the surgical intensive care unit (SICU) with the endotracheal tube in situ and was electively ventilated. A single dose of intravenous Fentanyl was required within the first 24 hours.

Extubation was successfully carried out on postoperative day 2 after thorough evaluation of clinical vitals, blood gas analysis, and chest radiography. On postoperative day 6, 0.5 ml of oral methylene blue was administered to assess for anastomotic integrity; absence of dye leakage confirmed successful repair, and enteral feeding was initiated.

The remainder of the postoperative course was uneventful. The patient was transferred to the ward on postoperative day 9 and discharged home in stable condition on day 15.

Discussion

Tracheoesophageal fistula (TEF) is a rare congenital anomaly, occurring in approximately 1 in every 2,500 live births [1]. In many low and middle income countries, surgical correction of TEF continues to be performed via open thoracotomy. This approach, while effective, is frequently associated with considerable postoperative challenges such as incisional pain, extended need for mechanical ventilation, and heightened risk of pulmonary complications.

Traditionally, caudal epidural analgesia has been used in combination with general anaesthesia in neonates undergoing TEF repair. This technique has demonstrated notable efficacy in improving postoperative pain control and in facilitating earlier weaning from mechanical ventilation. Kinottenbet *et al*. reported advancing a caudal catheter up to the T6–T7 vertebral level to enhance the effects of general anaesthesia. Their approach resulted in opioid-free analgesia and early extubation [2, 3]. In recent years, the thoracic paravertebral block (TPVB), particularly when guided by ultrasound, has emerged as a dependable regional anaesthetic technique. TPVB offers a favourable safety profile and has shown efficacy in providing high-quality perioperative analgesia in both thoracic and upper abdominal surgeries [4].

In our clinical experience, we utilized ultrasound-guided TPVB as part of a multimodal analgesia regimen in neonates undergoing TEF repair. Although postoperative ventilatory support is often required following thoracotomy, the neonates in our series exhibited smooth recovery, which we attribute in part to preserved pulmonary mechanics and the opioid-sparing benefits of effective regional analgesia.

Javier *et al*. documented the effective application of single-shot ultrasound-guided TPVB in neonates and infants undergoing pyloromyotomy, resulting in decreased opioid requirements and facilitating early extubation by minimizing central respiratory depression [5, 6]. Similarly, Thompson and Haynes documented the successful placement of thoracic paravertebral catheters in two neonates undergoing TEF repair, avoiding the need for continuous sedative or narcotic infusions [7]. The growing preference for PVB stems from its comparable analgesic efficacy to epidural techniques, with the added advantage of a lower risk profile [8].

In our series, single-shot TPVB provided adequate analgesia, minimized opioid requirements in the first 24 postoperative hours, and supported early extubation. Although we did not use continuous infusions, catheter placement under ultrasound guidance in the paravertebral space has been shown to reduce opioid needs and improve analgesic outcomes [9, 10].

Conclusion

With growing expertise in ultrasound-guided regional anaesthesia and a solid understanding of thoracic dermatomes and neural anatomy, TPVB—whether administered as a single shot or via catheter—can be an effective analgesic modality for neonates undergoing TEF repair. This technique not only supports early extubation but also reduces

postoperative opioid use and related complications. Nonetheless, larger randomized trials are needed to validate its efficacy and safety in neonatal populations.

References

1. Spitz L. Oesophageal atresia. Orphanet J Rare Dis. 2007;2:24. https://doi.org/10.1186/1750-1172-2-24
2. Bosenberg AT, Hadley GP, Wiersma R. Esophageal atresia: Caudothoracic epidural anesthesia reduces the need for postoperative ventilator support. Pediatr Surg Int. 1992;7:289-91. https://doi.org/10.1111/pan.12240
3. Kinoenbelt G, Skinner A, Seefelder C. Tracheo-esophageal fistula (TOF) and esophageal atresia (OA). Best Pract Res Clin Anaesthesiol. 2010;24:387-401. https://doi.org/10.1016/j.bpa.2010.02.010
4. Boretsky K, Visoiu M, Bigeleisen P. Ultrasound-guided approach to the paravertebral space for catheter insertion in infants and children. Pediatr Anesth. 2013;23:1193-8. https://doi.org/10.1111/pan.12238
5. Mata-Gómez J, Guerrero-Domínguez R, García-Sangosa M, Ontanilla A. Ultrasound-guided paravertebral block for pyloromyotomy in 3 neonates with congenital hypertrophic pyloric stenosis. Rev Bras Anestesiol. 2015;65(4):302-5. https://doi.org/10.1016/j.bjane.2014.03.012
6. Ali MA, Akbar AS. Report of a case of ultrasound-guided continuous thoracic paravertebral block for post-thoracotomy analgesia in a child. Middle East J Anaesthesiol. 2013;22:107-8. https://doi.org/10.5152/TJAR.2016.32448
7. Thompson ME, Haynes BRN. Ultrasound-guided thoracic paravertebral block catheter experience in 2 neonates. J Clin Anesth. 2015;27(6):514-6. https://doi.org/10.1016/j.clinane.2015.05.002
8. Page EA, Taylor KL. Paravertebral block in paediatric abdominal surgery—a systematic review and meta-analysis of randomized trials. Br J Anaesth. 2017;118(2):159-66. https://doi.org/10.1093/bja/aew436
9. Sahajanandan R, Varsha AV, Kumar DS, *et al*. Efficacy of paravertebral block in "fast-tracking" pediatric cardiac surgery—Experiences from a tertiary care center. Ann Card Anaesth. 2021;24(1):24-9. https://doi.org/10.4103/aca.ACA_83_19
10. Thompson ME, Haynes B. Ultrasound-guided thoracic paravertebral block catheter experience in 2 neonates. J Clin Anesth. 2015;27(6):514-6. https://doi.org/10.1016/j.clinane.2015.05.002

Copyright and License

© 2025 The Author(s). Authors retain the copyright of their published articles.

This is an open access journal, and articles are distributed under the terms of the Creative Commons Attribution NonCommercial-ShareAlike 4.0 International (CC BY-NC-SA 4.0) License, which allows others to remix, tweak, and build upon the work non-commercially, as long as appropriate credit is given and the new creations are licensed under the identical terms.

Deed - Attribution-NonCommercial-ShareAlike 4.0 International - Creative Commons